

ALPHA DENT

Case Report

Immediate implantation with immediate loading All-on-4

by using intraoral welding I.O.W.

Authors: **Nigai Igor Alexandrovich**, a highly qualified dentist-surgeon, orthopedist

Clinic: **Dental clinic H+.**

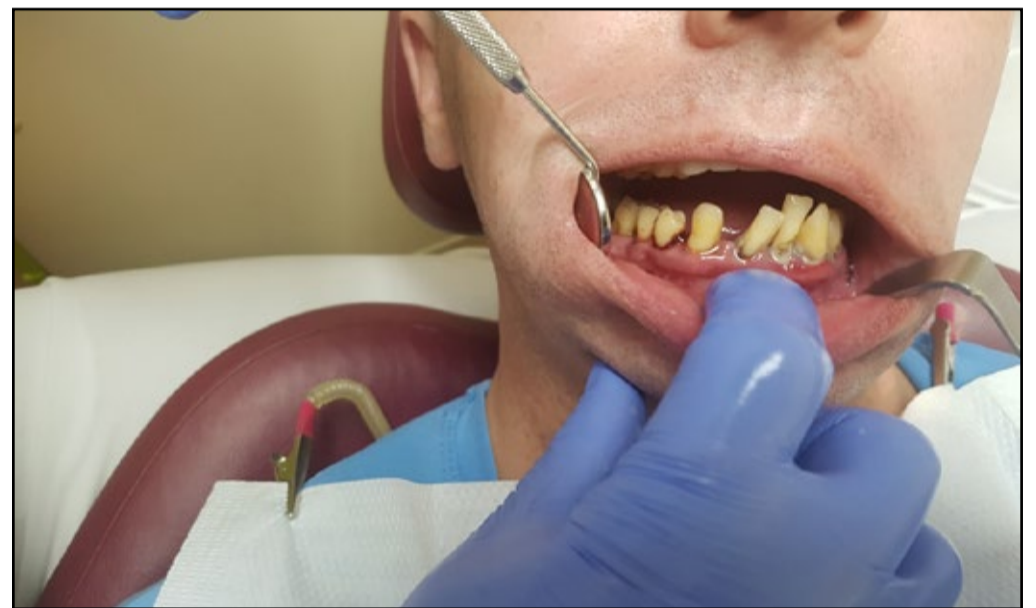
A patient addressed with generalized periodontitis of teeth of the lower jaw. The patient wished to restore the teeth with the help of permanent structure as soon as possible.

We decided to make immediate implantation with immediate loading. After exodontia and implant insertion, a fixed acrylic prosthesis with the bar was made according to the method of intraoral welding.

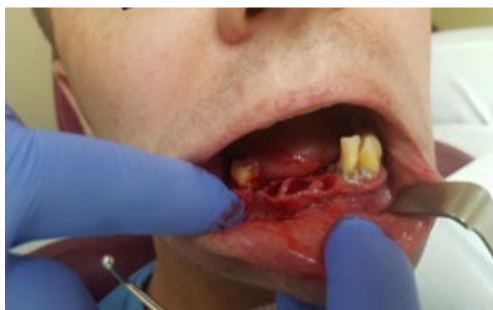The basis for the method of intraoral welding is an emergence in argon environment of the electric arc between two cyclohexanones, or Syncrystalli-

zation. The method allows creating the frame for immediate loading.

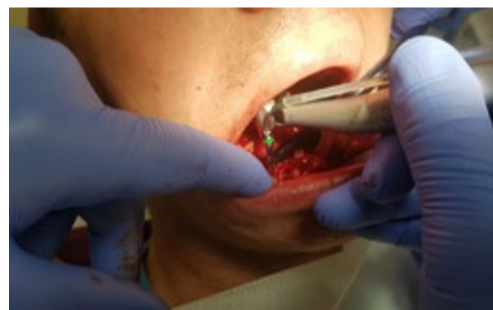In this medical case during one visit all teeth of the lower jaw were extracted, 4 implants Alpha Dent Classic with the internal hex were placed, the frame was made in the mouth with the help of the apparatus I.O.W., impressions for temporary dentures were removed and after 3 days a temporary screw-retained prosthesis was placed.



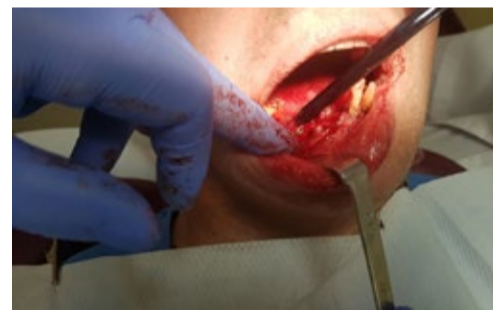Initial situation



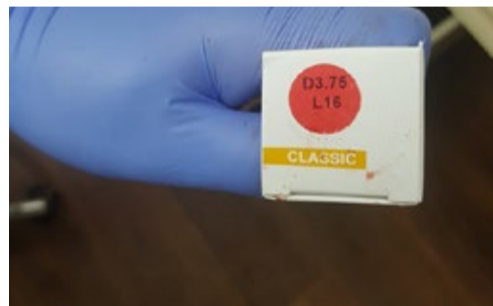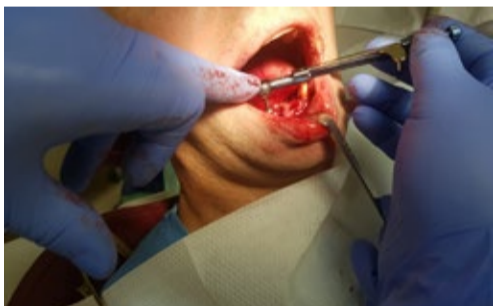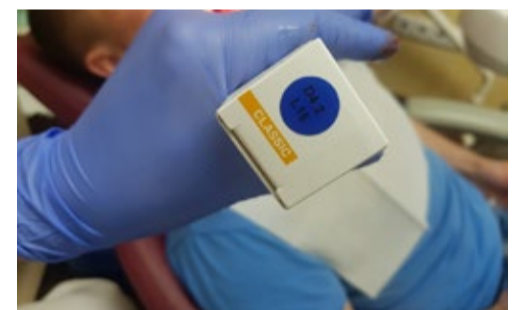Extraction of the damaged teeth of the lower jaw



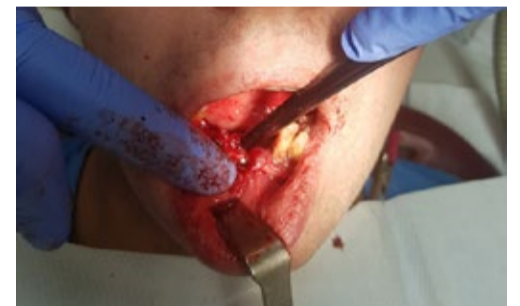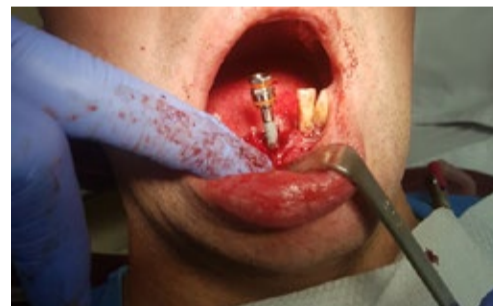Drilling of alveolar socket for implant insertion



Immediate insertion of the implant Alpha Dent Classic in the lower jaw (D 4.2, L16).

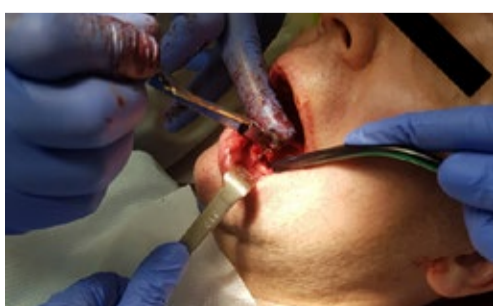


Insertion of the second implant Alpha Dent Classic in the lower jaw (D 3.75, L16).

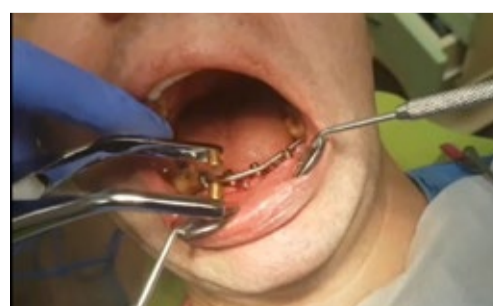


Insertion of the third implant Alpha Dent Classic in the lower jaw (D 3.75, L13)

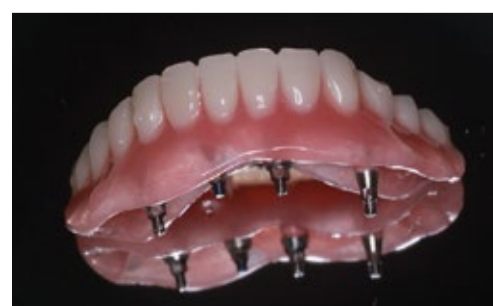Insertion of the fourth implant Alpha Dent Classic on the lower jaw (D 4.3, L16).



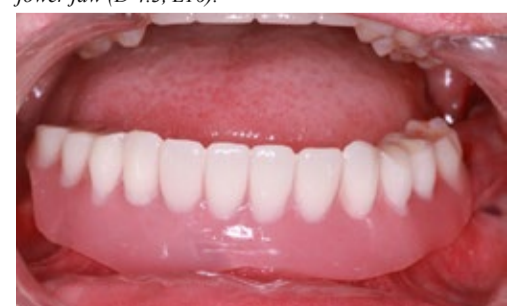Implant driver-adaptor and fixation of implants with torque-controlled wrench



Intraoral welding



Ready for insertion temporary denture with dental backing for immediate loading. View of the placed temporary denture in the patient's mouth



ALPHA DENT

Case Report

All-on-6 Alpha Dent. Immediate Implantation of Maxilla Within 72 Hours

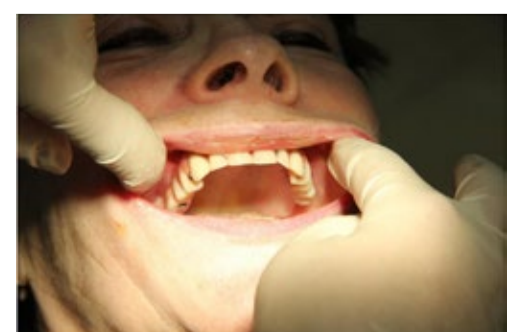
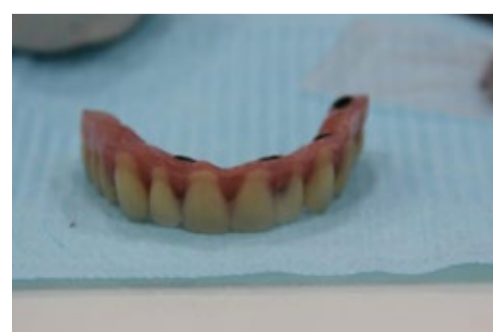
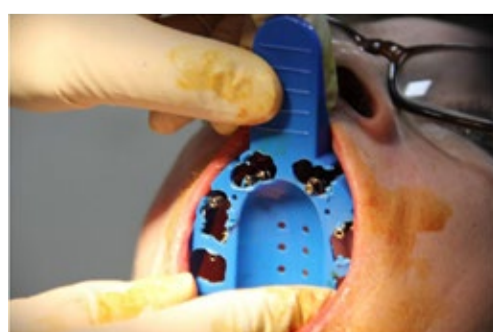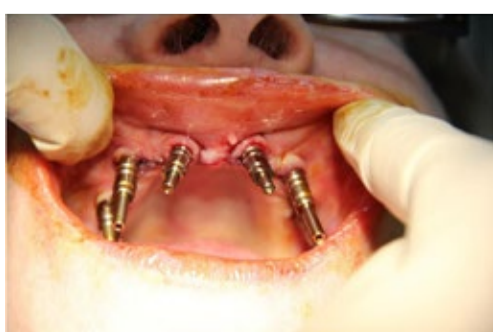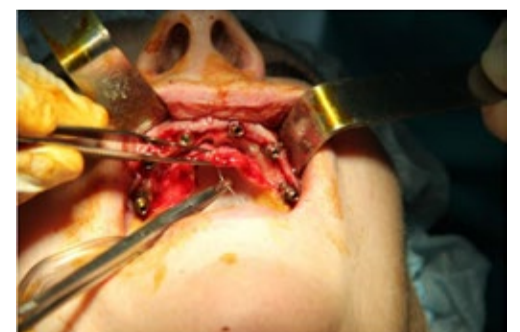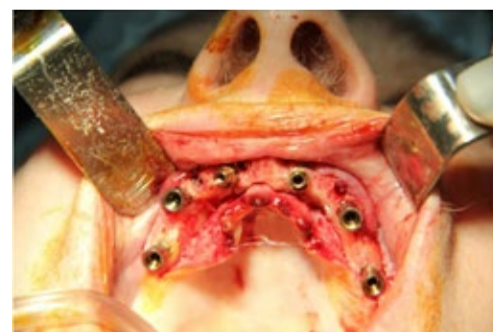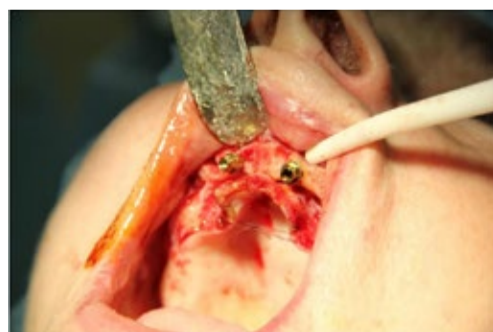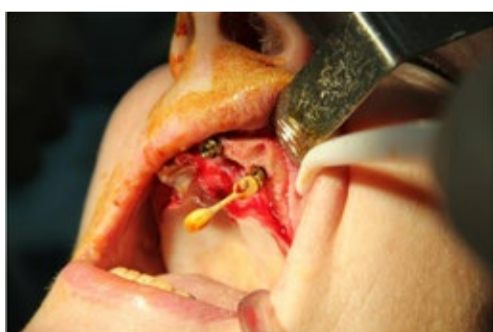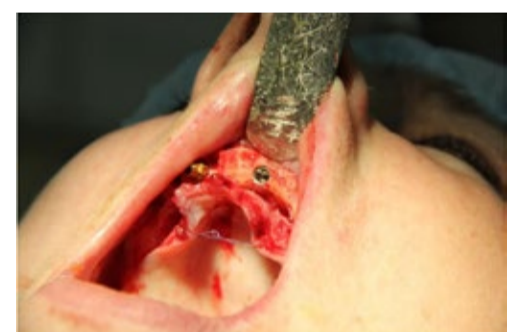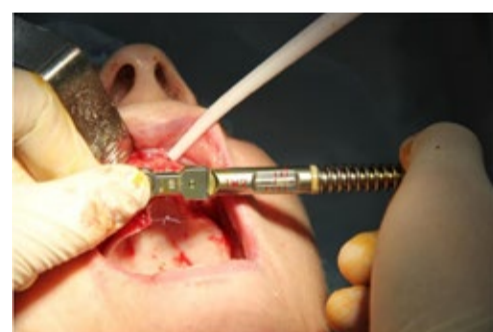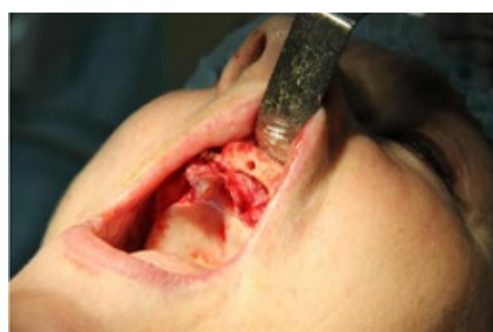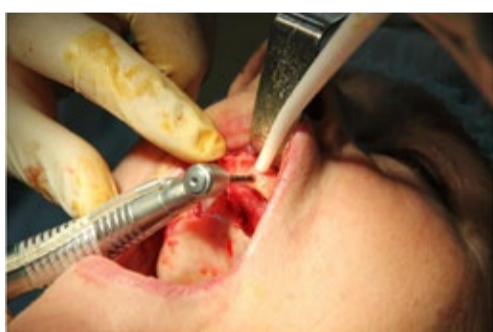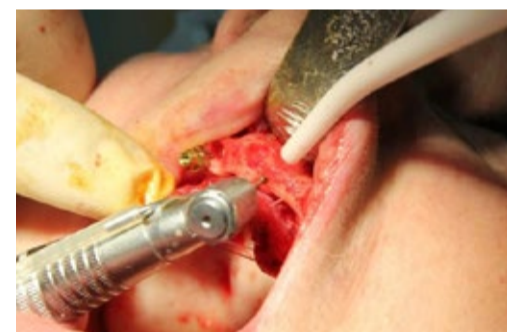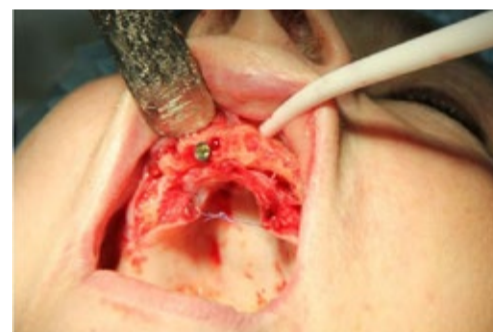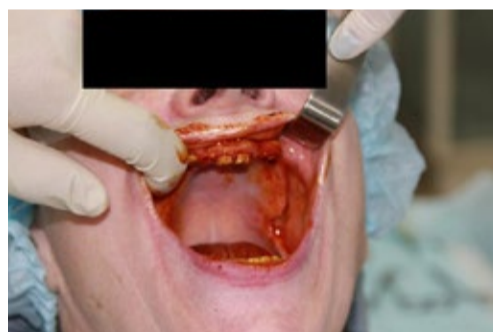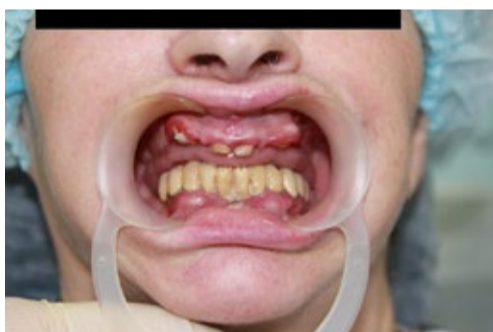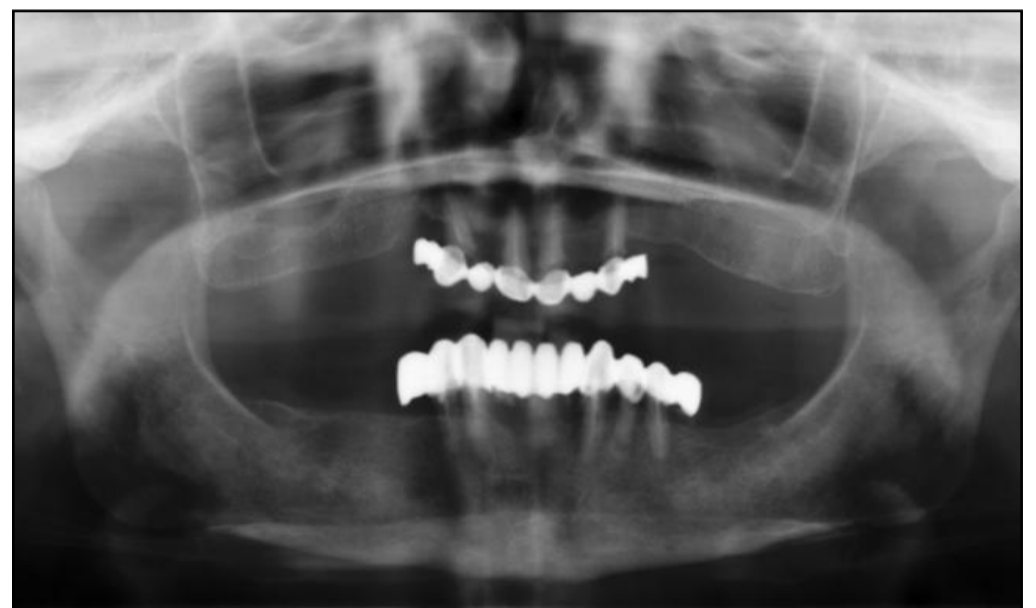Authors:
Namdakov Nikolai Vladimirovich,
Implant surgeon, maxillofacial surgeon,
orthopedist, experience over 13 years;
Filimonov Oleg Vladimirovic, Implant
surgeon, maxillofacial surgeon, orthope-
dist, experience over 18 years.

Clinic: "Smile-At-Once",
Moscow, the Russian Federation.

The patient's medical history: Allergic reaction to cold, Arbidol, Tetracycline;
A microstroke in 2014; Arterial hypertension, IHD; Takes antiaggregants permanently.

Diagnosis: Partially missing teeth in the maxilla and mandible. Chronic generalized
periodontitis.

Treatment plan: Complex implantation in maxilla, All-on-6 with Alpha Dent im-
plants; Extraction of all maxillary teeth; Alveolar curettage; Reduction of the alveolar
crest on maxilla by 0.5 mm.; Placing of conditional-permanent, hybrid, metal-
lic-acrylic implants under the immediate loading protocol within 72 hours.



ALPHA DENT

Case Report

Implantation and immediate placing within 72 Hours

Unique case report All-on-6 with implants Alpha Dent Active Conus

Authors:
Namdakov Nikolai Vladimirovich
Implant surgeon, maxillofacial surgeon,
orthopedist, experience over 13 years;

Filimonov Oleg Vladimirovich
Implant surgeon, maxillofacial surgeon,
orthopedist, experience over 18 years

Clinic:
"Smile-At-Once", Moscow, the Russian
Federation.

Diagnosis:
Partially missing teeth in maxilla and mandible;
Chronic generalized periodontitis.

